

Elbow:

2/9/18

Cor PD FS

Sagittal PDFS

Axial PDFS

Axial T1

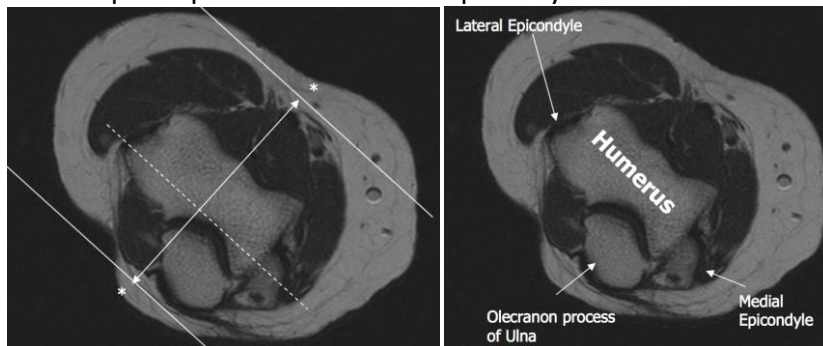
If arthrogram, add:

Cor T1 FS

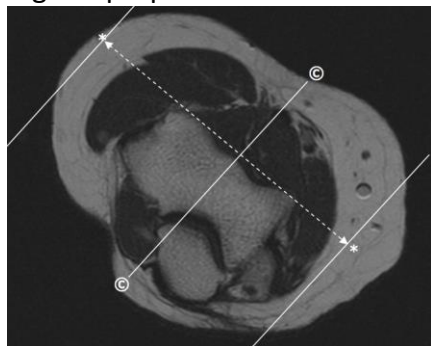
Sagittal T1 FS

**Please include FABS views if concern for biceps tendon rupture

Coronal plane parallel to humeral epicondyles



Sagittal perpendicular to coronal © plane



Axial plane perpendicular to coronal ©; humeral metaphysis **THROUGH** radial tuberosity.

