

Hip (unilateral hip pain)

Coronal STIR Sacrum to PS (pelvis, large FOV); FOV 35-40, 3/1, TE 50-60

Coronal T1 (symptomatic hip); FOV 16-18, 3/0.5

Coronal PDFS; FOV 16-20, 3/.05

Axial PDFS; FOV 16-20, 3/0.5

Sagittal PDFS; FOV 16-20, 3/0.5

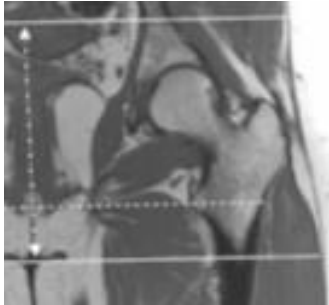
Hip with arthrogram, add:

Coronal T1FS: FOV 16-18, 3/0.5

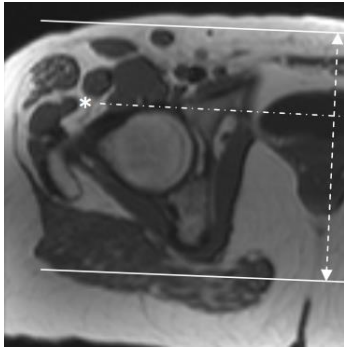
Coronal T2 (NO fat sat): FOV 16-18, 3/0.5

Axial T2 (NO fat sat): FOV 16-18, 3/0.5

Orient axial from superior acetabulum through lesser trochanter



Orient coronal parallel to the femoral heads. Scan from ischium through pubic symphysis.



Orient sagittal perpendicular to coronal. Scan acetabulum through greater troch.

