

Thumb

Cor PD; FOV 10, 3/0.3

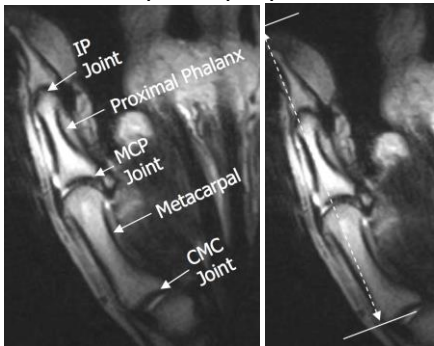
Cor PDFS; FOV 10, 3/0.3

Axial PDFS; FOV 10, 3/0.3

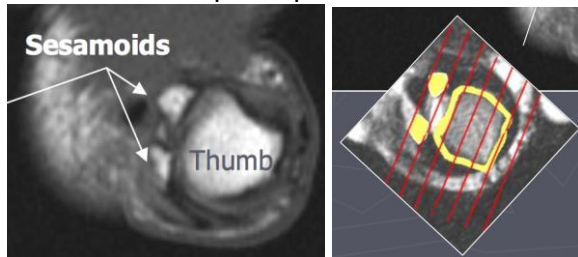
Axial PD; FOV 10, 3/0.3

Sagittal PDFS; FOV 10-14, 3/0.3

Orient axial plane perpendicular to midshaft of proximal thumb phalanx.



*Orient coronal plane parallel to thumb sesamoid bones, scan through entire thumb



Orient sagittal plane perpendicular to coronal plane, scan through entire thumb.

