

Wrist:

Cor T1; FOV 8-12, 3/0.5

Cor PDFS; FOV 8-12, 3/0.5

Cor 3d Gre; 8-12, 1/0

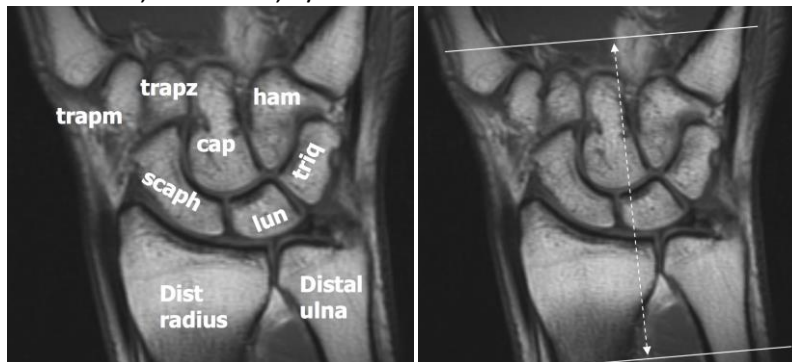
Sagittal PDFS; FOV 10-12, 3/1

Axial PDFS; FOV 8-12, 3/1

If arthrogram, add:

Cor T1 FS; FOV 8-12, 3/0.5

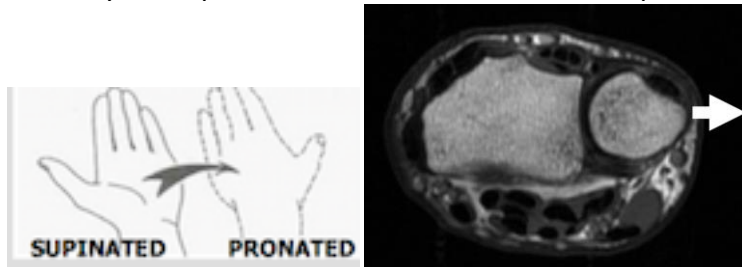
Axial T1 FS; FOV 8-12, 3/0.5



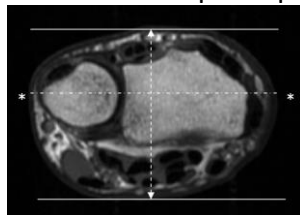
Orient axial plane parallel to distal radius. Scan from radial metaphysis through proximal metacarpals.

Scan wrist in PRONATION.

Ulnar styloid is pointed to the side when wrist is pronated, as below.



Orient coronal plane parallel to line drawn through ulnar and radial styloid



Orient sagittal plane perpendicular to the coronal plane ©

